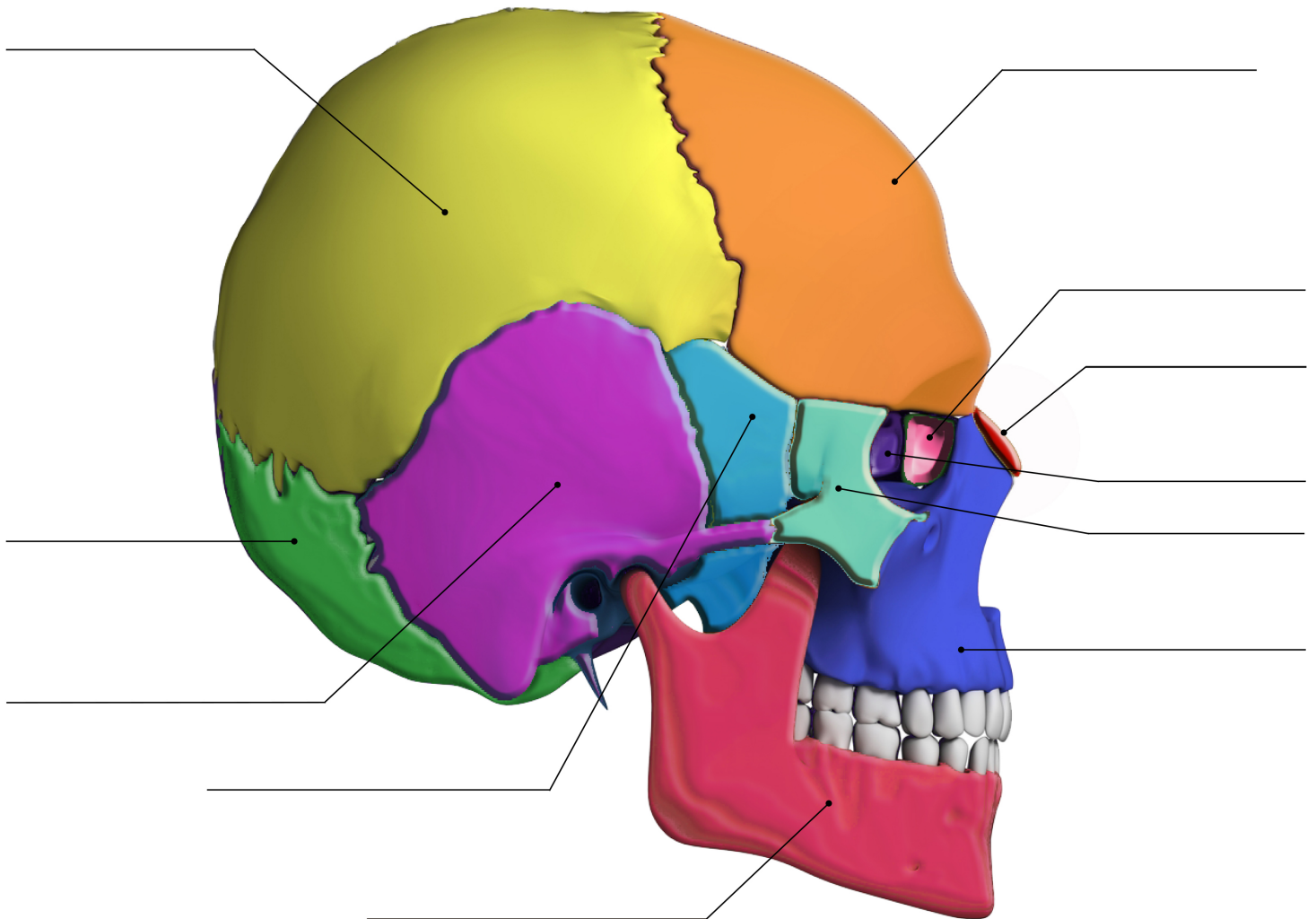


## SKULL BONES

### WORKSHEET

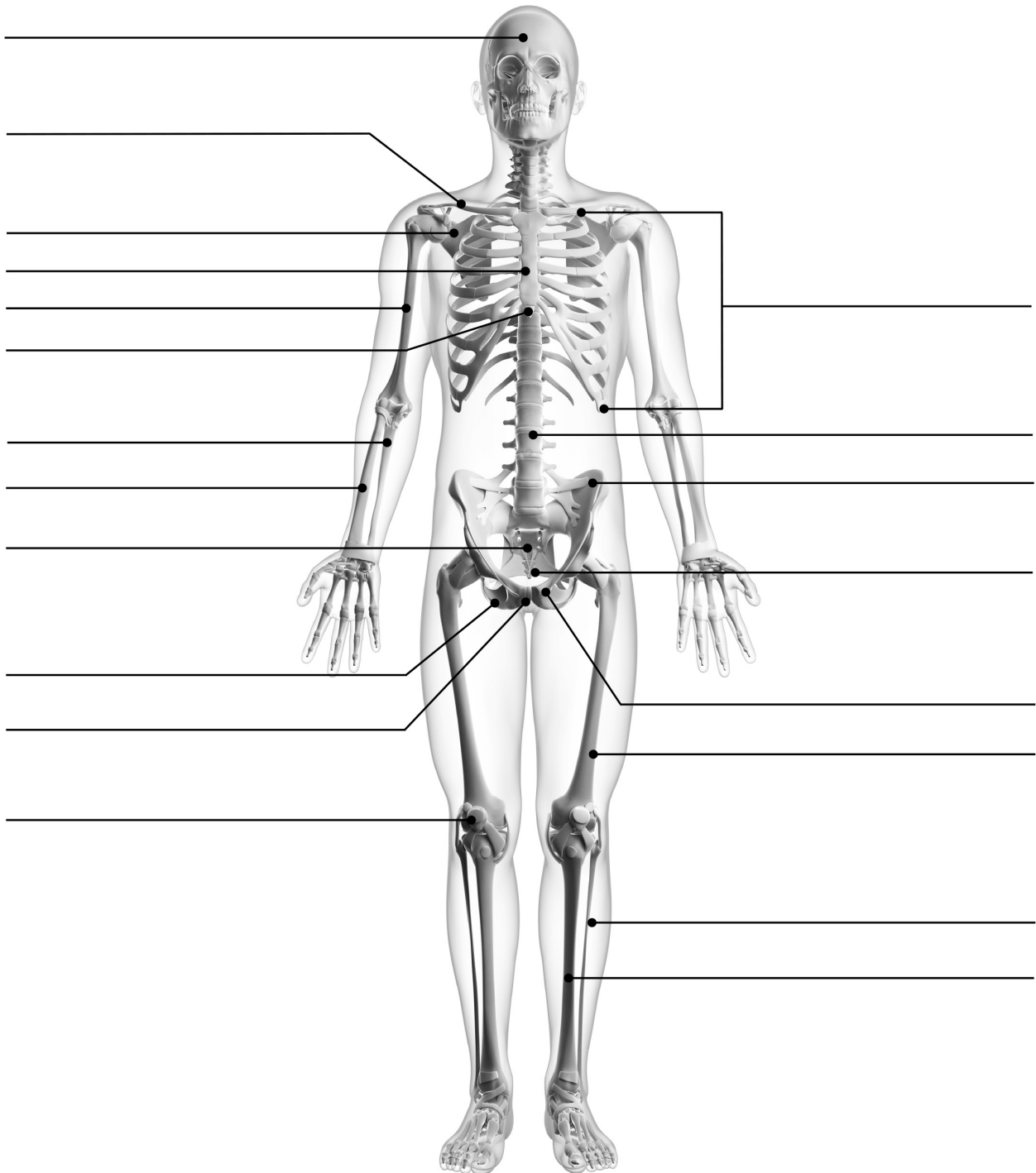


**IDENTIFY AND LABEL THE BONES OF THE SKULL:**

**Occipital, Mandible, Sphenoid, Frontal, Nasal, Maxilla, Lacrimal, Ethmoid, Zygomatic, Temporal, Parietal**

# SKELETON

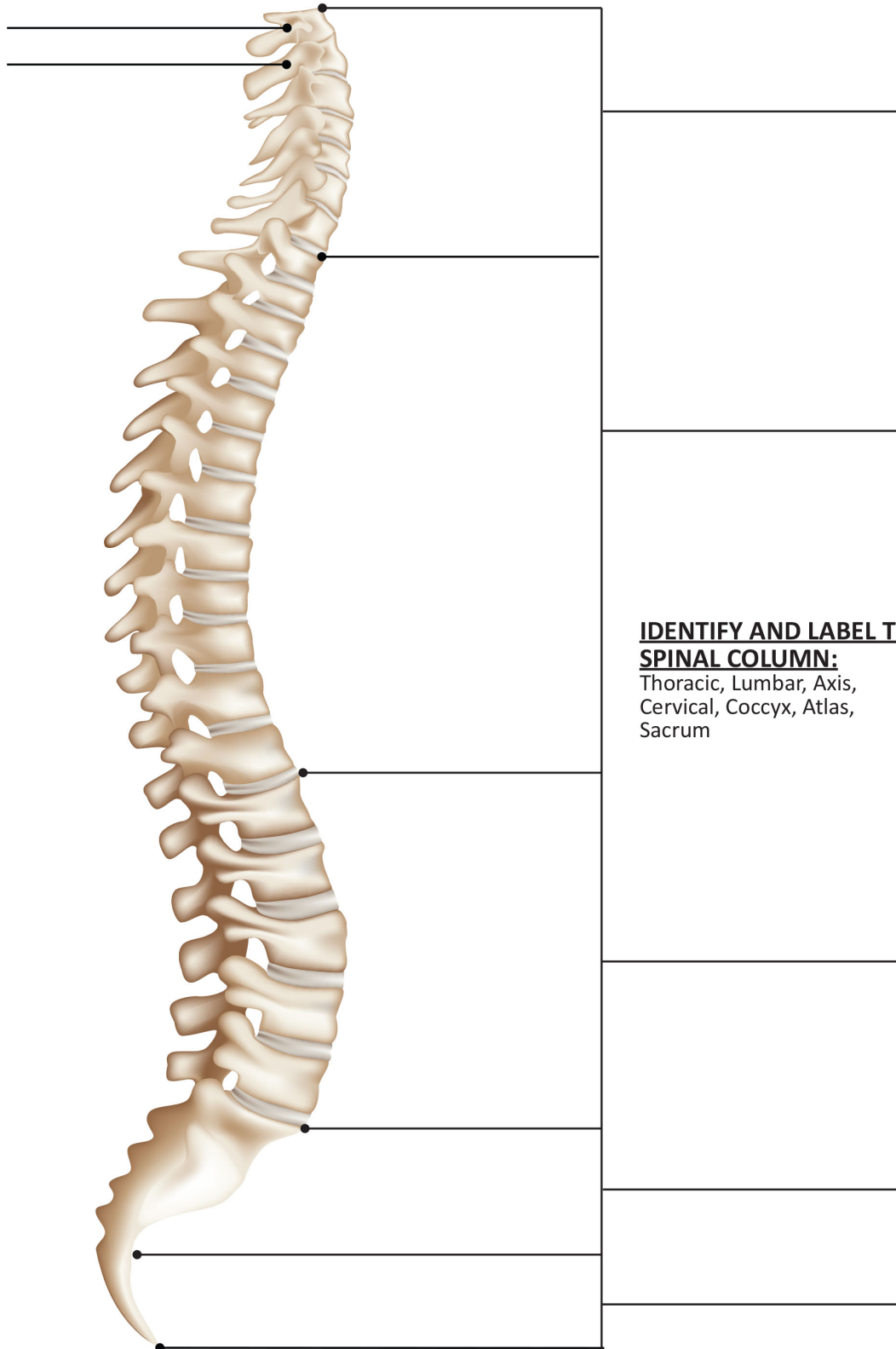
## WORKSHEET



**IDENTIFY AND LABEL THE SKELETAL BONES:**

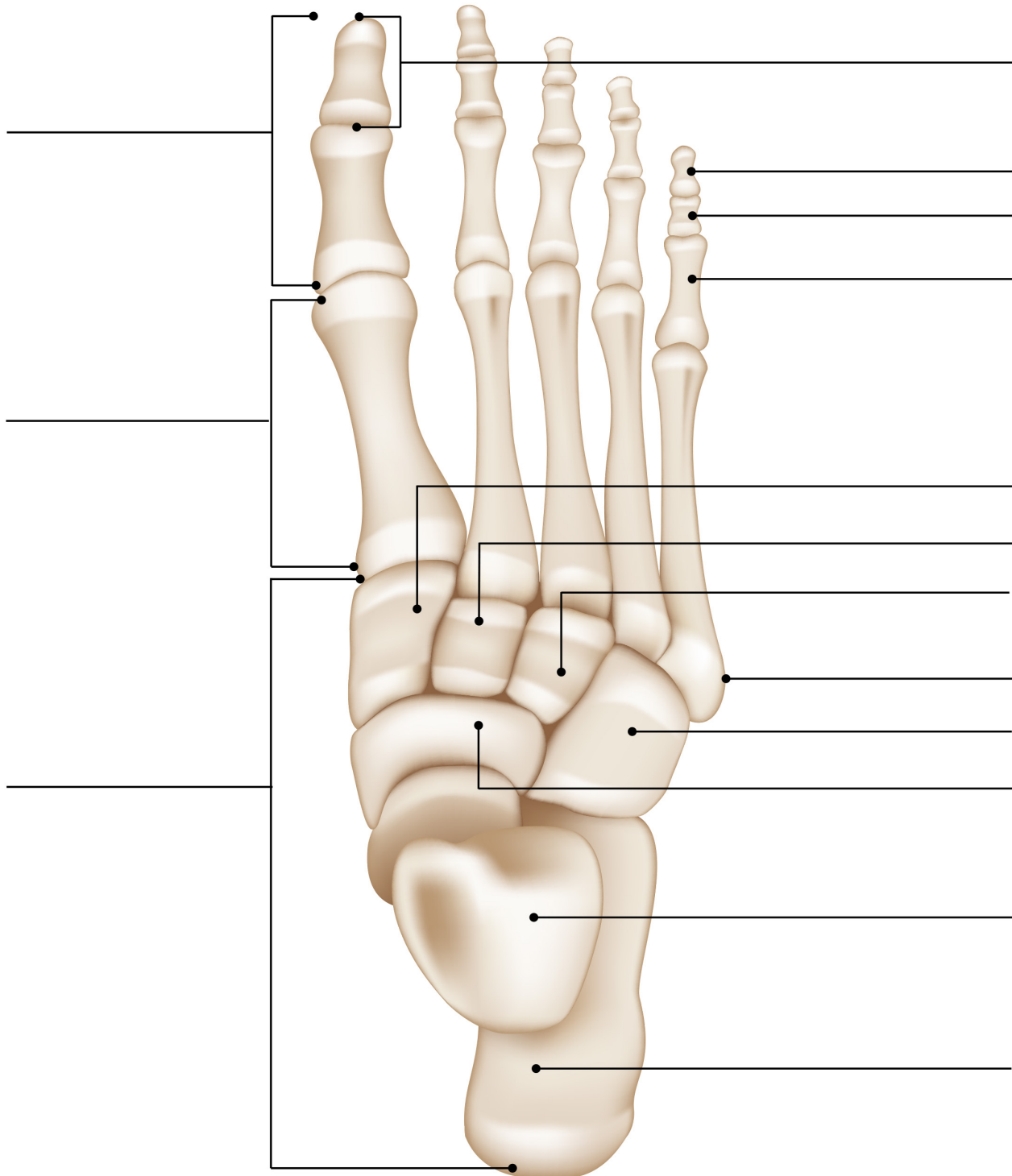
Skull, Tibia, Fibula, Femur, Patella, Humerus, Ulna, Radius, Sternum, Clavicle, Vertebral Column, Xiphoid Process, Coccyx, Pubic Bone, Ilium, Rib Cage, Ischium, Scapula, Sacrum, Pubic Symphysis

# VERTEBRAL COLUMN (VERTEBRAE) WORKSHEET



# BONES OF THE FOOT

## WORKSHEET

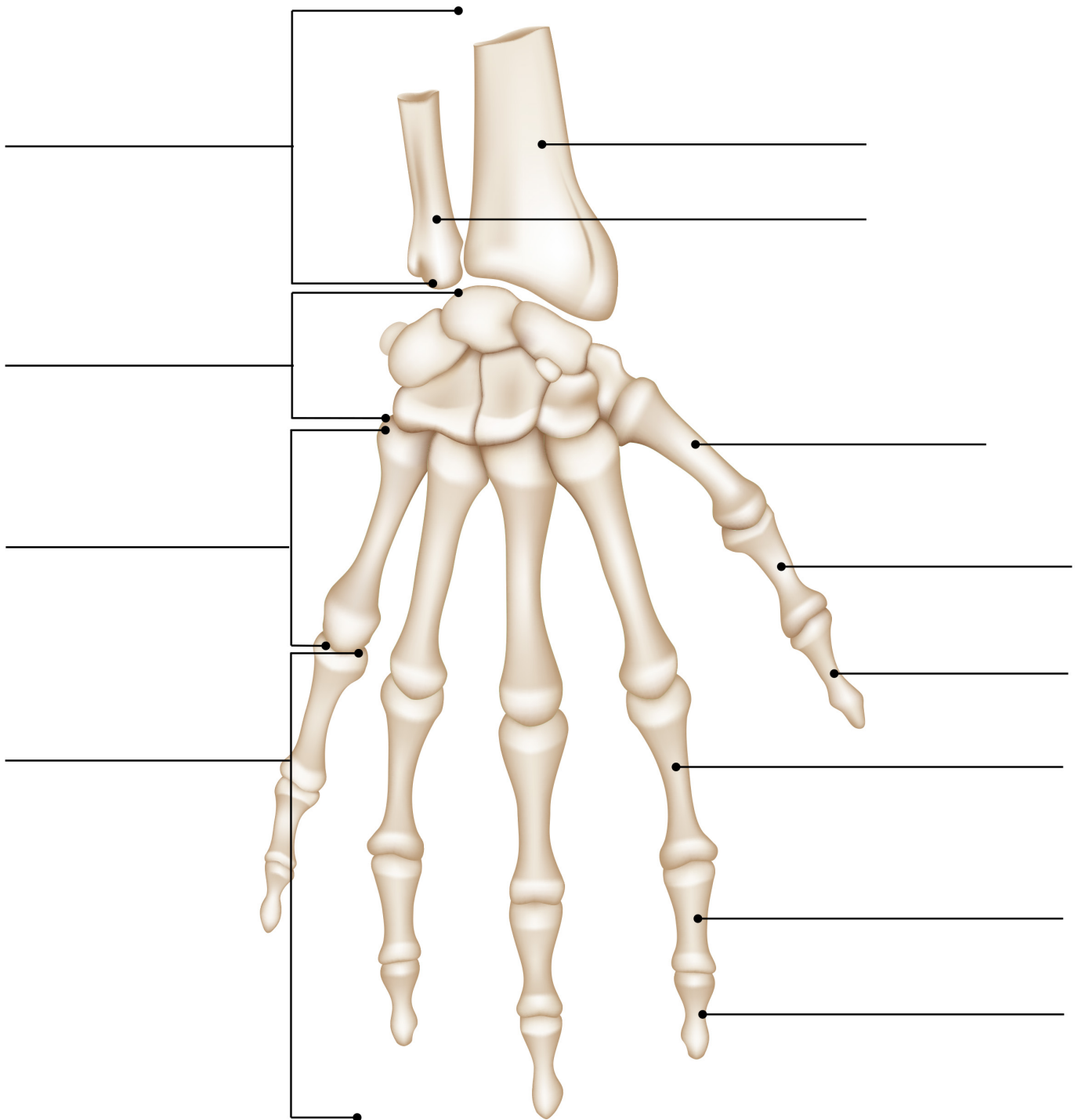


### **IDENTIFY AND LABEL THE BONES OF THE FOOT:**

**Calcaneus, Proximal Phalanges, Tarsal Bones, Lateral Cuneiform, Medial Cuneiform, Navicular, Talus, Hallux, Phalange Bones, Intermediate Cuneiform, Middle Phalanges, Cuboid, Distal Phalanges, Metatarsal Bones, Styloid Process**

# BONES OF THE HAND

## WORKSHEET

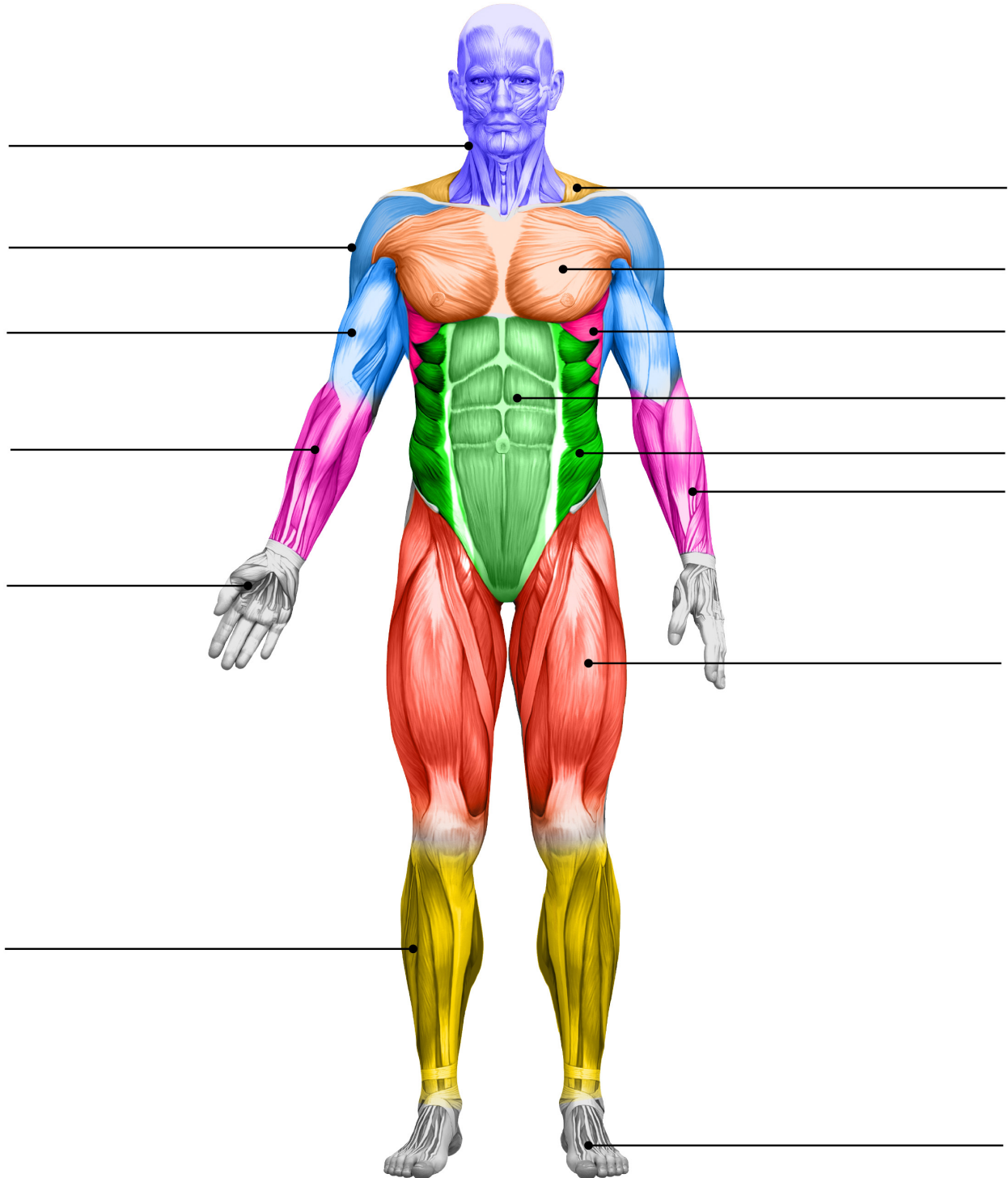


### **IDENTIFY AND LABEL THE BONES OF THE HAND:**

**Phalange Bones, Bones of the Forearm, Radius Bone, Proximal Phalange, Middle Phalange, Metacarpal Bones, Ulna Bone, Carpel Bones, Distal Phalange, Distal Phalange, Proximal Phalange, Metacarpal Bone**

# MAJOR SUPERFICIAL MUSCLE GROUPS

## WORKSHEET 1



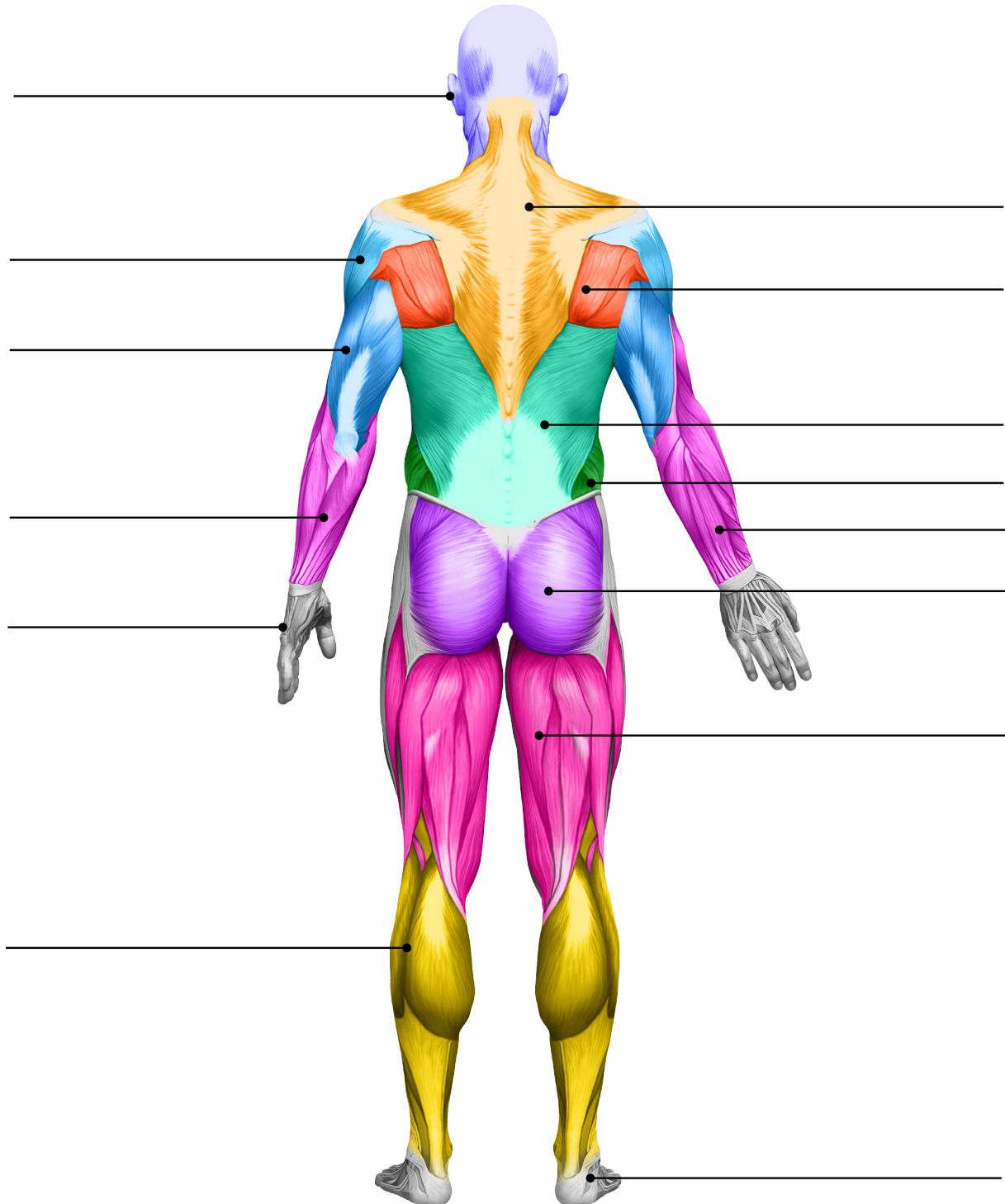
**IDENTIFY AND LABEL THE MAJOR SUPERFICIAL MUSCLE GROUPS:**

**Abdominals, Obliques, Biceps, Calves, Pectorals, Flexors/Extensors (2 places), Deltoid, Trapezius, Head/Neck, Serratus, Quadriceps, Hands, Feet**



# MAJOR SUPERFICIAL MUSCLE GROUPS

## WORKSHEET 2



### IDENTIFY AND LABEL THE MAJOR SUPERFICIAL MUSCLE GROUPS:

**Obliques, Triceps, Calves, Flexors/Extensors (2 places), Deltoid, Trapezius, Head/Neck, Hands, Feet, Spinatus-Teres, Gluteus, Latissimus, Hamstrings**